



ارائه شده توسط:

سایت ترجمه فا

مرجع جدیدترین مقالات ترجمه شده

از نشریات معتبر



Basic nutritional investigation

Bioactive compounds, antioxidant potential, and hepatoprotective activity of sea cucumber (*Holothuria atra*) against thioacetamide intoxication in rats

Amr Y. Esmat Ph.D.^{a,*}, Mahmoud M. Said Ph.D.^a, Amel A. Soliman Ph.D.^b,
Khaled S.H. El-Masry Ph.D.^c, Elham Abdel Badiea B.Sc.^a

^a Department of Biochemistry, Faculty of Science, Ain Shams University, Cairo, Egypt

^b Department of Histology, Faculty of Medicine, Ain Shams University, Cairo, Egypt

^c Department of Aroma and Flavors, National Research Center, Cairo, Egypt

ARTICLE INFO

Article history:

Received 13 January 2012

Accepted 4 June 2012

Keywords:

Holothuria atra extract

High-performance liquid chromatographic analysis

In vitro antioxidant studies

Thioacetamide

Liver function tests

Antioxidant enzymes

Histologic studies

Rats

ABSTRACT

Objective: The identification of the active phenolic compounds in the mixed extract of sea cucumber (*Holothuria atra*) body wall by high-performance liquid chromatography and an assessment of its hepatoprotective activity against thioacetamide-induced liver fibrosis in rats.

Methods: Female Swiss albino rats were divided into four groups: normal controls; oral administration of a sea cucumber mixed extract (14.4 mg/kg of body weight) on days 2, 4, and 6 weekly for 8 consecutive weeks; intoxication with thioacetamide (200 mg/kg of body weight, intraperitoneally) on days 2 and 6 weekly for 8 wk; and oral administration of a sea cucumber extract and then intoxication with thioacetamide 2 h later for 8 wk.

Results: High-performance liquid chromatographic analysis of the sea cucumber mixed extract revealed the presence of some phenolic components, such as chlorogenic acid, pyrogallol, rutin, coumaric acid, catechin, and ascorbic acid. In vitro studies have shown that the extract has a high scavenging activity for the nitric oxide radical, a moderate iron-chelating activity, and a weak inhibitory effect of lipid peroxidation. The subchronic oral administration of sea cucumber extract to the rats did not show any toxic side effects but increased hepatic superoxide dismutase and glutathione peroxidase activities. The coadministration of sea cucumber extract and thioacetamide (protection modality) normalized serum direct bilirubin, alanine and aspartate aminotransferases, hepatic malondialdehyde, and hydroxyproline concentrations and antioxidant enzyme activities. In addition, the histologic examination of liver sections from the protection group that were stained with hematoxylin and eosin showed substantial attenuation of the degenerative cellular changes and regressions in liver fibrosis and necrosis induced by the thioacetamide intoxication.

Conclusion: Sea cucumber mixed extract contains physiologically active phenolic compounds with antioxidant activity, which afforded a potential hepatoprotective activity against thioacetamide-induced liver injury in a rat model.

© 2013 Elsevier Inc. All rights reserved.

Introduction

The sea cucumber (*Holothuria*) is a marine invertebrate of the phylum Echinoderm and the class Holothuroidea found on the sea floor worldwide [1]. There are more than 1000 species of sea cucumber, and approximately 20 are edible. Sea cucumber is a delicacy food in China and Asian countries. In addition to their good flavor, sea cucumbers are commonly used to treat wounds, eczema, arthritis, hypertension, and impotence [2,3]. The sea

cucumber is a healthy food because it contains different physiologically active substances, including vitamins (A, C, B1, B2, and B3), trace elements (calcium, iron, magnesium, and zinc), polysaccharides (chondroitin sulfate), and saponin glycosides [4]. Furthermore, some bioactive compounds extracted from holothurians have been reported to have anti-inflammatory [5], antitumor [6], and fungicidal [7] activities. Most studies on the sea cucumber of the Red Sea (*H. atra*) have been taxonomic [8–10].

Oxidative stress is known to play an important role in liver injury [11]. Recent interest in food phenolics has increased owing to their roles as antioxidants and scavengers of reactive oxygen species and free radicals and their implied role in the prevention

* Corresponding author. Tel.: +202-2632-7394; fax: +202-2684-2123.
E-mail address: amryesmat@yahoo.com (A. Y. Esmat).

of many pathologic diseases, such as heart and liver diseases [12]. Alternatively, phenolic compounds have been found to increase endogenous defense mechanisms, stimulate the antioxidant response element that regulates the gene expression of enzymes involved in phase II metabolism of xenobiotics and antioxidant defense, and exhibit inhibitory effects on membrane lipid peroxidation [13].

The present study was undertaken to identify the bioactive phenolic compounds in the *H. atra* body wall mixed extract and to evaluate its hepatoprotective potential against thioacetamide (TAA)-induced liver fibrosis in rats. The aim of the study was extended to determine the antioxidant efficacy of the extract in cell-free systems.

Materials and methods

Sample collection and preparation

Sea cucumbers (*H. atra*) caught from the Red Sea (Hurghada) were kindly provided by Dr. Mohamed Zaki (Laboratory of Marine Biochemistry, National Institute of Oceanography and Fisheries, Suez and Aqaba Gulfs branch). The animals were transported to our laboratory in an ice box containing ice cubes and a few pinches of table salt. The animals were immediately washed under running tap water and cut open, and all visceral organs were removed. The animals were rinsed thoroughly of any internal organs or body fluids, and then the body walls of the animals were stored at -20°C until processing.

Preparation of sea cucumber mixed (organic/aqueous) extract

The adopted extraction technique was previously described by Haug et al. [14], with slight modifications. The body walls of the animals were cut into small parts, finely ground in a blender, and then poured in Petri dishes. The Petri dishes were precisely weighed and placed in an oven at 70°C for 18 to 20 h until no change in weight was recorded. The dried samples were blended further with a pestle until a fine powder was produced. The weight of the fine powder was suspended in 10 vol of a mixture of acetonitrile and 0.1% trifluoroacetic acid at a proportion of 60:40 (v/v) and stirred continuously in the dark for 24 h using a magnetic stirrer. The extract was centrifuged at 3000 rpm for 20 min and the supernatant was aspirated into a dry flask and kept at 4°C . The extraction was repeated twice on the residue and the supernatants were combined. The mixed extract was kept at 4°C for 24 h until the organic solvent was completely evaporated and then freeze-dried at -50°C for 36 h.

Chemical studies

Analysis of metabolic compounds

Total soluble protein, carbohydrate, and lipid contents were determined in the sea cucumber mixed extract according to the methods of Lowry et al. [15], Dubois et al. [16] and Knight et al. [17], respectively.

High-performance liquid chromatographic analysis

The phenolic components of sea cucumber extract were separated by high-performance liquid chromatography using an Agilent 1100 device (Waldborn, Germany) equipped with a Zorbax reversed-phase 300SB C_{18} column (250×4.6 mm) with $5\text{-}\mu\text{m}$ particle size (Lawrence, KS, USA) and ultraviolet detector (G1314A) adjusted at 280 nm. Sample and authentic standards (50 μL ; chlorogenic acid, coumaric acid, catechin, ascorbic acid, pyrogallol, and rutin) dissolved in dimethyl sulfoxide and acidified with a drop of acetic acid were injected onto the column. The mobile phase was 0.4% formic acid and acetonitrile (60:40, v/v), with a constant flow rate of 1 mL/min. The isolated peaks of the phenolic compounds in the sample were identified by comparing their relative retention times with those of the standards, and then the concentration (percentage) of each compound was calculated as peak area integration.

Biochemical studies

Animals

Adult female Swiss albino rats weighing 150 to 200 g were used throughout this study. The animals were housed in steel mesh cages (five per cage) and had free access to a commercial pellet diet and tap water for 1 wk before the start of the experiment as an acclimatization period. All animal experiments were performed under protocols approved by the local institutional animal ethics committee of Ain Shams University.

Preparation and administration of sea cucumber mixed extract

A stock solution of sea cucumber mixed extract in polypropylene glycol (Bioshop, Ontario, Canada) was prepared, stored at 4°C , and replaced weekly. Overnight-fasted rats were administered with the sea cucumber extract by intragastric tubing at a dose level of 14.40 mg/kg of body weight three times weekly (days 2, 4, and 6) for 8 consecutive weeks. The implemented dose was chosen based on a preliminary assessment of acute toxicity. The acute toxicity for the two doses of the extract (low dose 14.40 mg/kg of body weight, high dose 28.80 mg/kg of body weight, equivalent to 1000 and 2000 mg/70 kg of human body mass, respectively) was carried out in 10 female Swiss albino rats. The animals showed neither mortality nor toxicity symptoms after 24 h of treatment.

Experimental chemical induction of liver fibrosis

Liver fibrosis was induced in the animals according to the method of Toyama et al. [18], with slight modifications. Rats were injected intraperitoneally with freshly prepared TAA (Sigma, St. Louis, MO, USA) in sterile saline (200 mg/kg of body weight) twice weekly (days 2 and 6) for 8 consecutive weeks.

Study design

Sixty-two adult female Swiss albino rats were randomly assorted into four groups: 1) rats were injected intraperitoneally with polypropylene glycol and served as normal controls (NC group, $n = 10$); 2) rats were orally administered with sea cucumber extract (Ex group, $n = 12$); 3) rats were intoxicated with TAA and served as negative controls (TAA group, $n = 20$); and 4) rats received by gavage the sea cucumber extract and then intoxicated intraperitoneally with TAA 2 h later (protective; Ex + TAA group, $n = 20$).

Collection and sampling of blood and some body organs

At the end of the experiment (8 wk), the animals were weighed and blood samples were taken from the retro-orbital venous plexus under light ether anesthesia after a fast of 12 h. Serum was separated from the clotted blood samples by centrifugation at 5000 rpm for 5 min and then aliquoted and analyzed. Animals were thoracotomized and then the liver, heart, kidneys, and spleen were dissected out, rinsed in isotonic sterile saline, blotted dry on a filter paper, and weighed. The ratio of organ weight to total body weight was calculated as a useful index of toxicity [19]. A small part from the right lobe of the liver was cut and fixed for 3 d in 10% phosphate buffered formalin (pH 7.2) at 4°C for histologic examination. The remaining liver tissue was placed in a plastic vial containing ice-cold sterile saline and stored at -80°C until biochemical analysis.

Preparation of liver homogenate

Malondialdehyde (MDA) and hydroxyproline contents were estimated in 20% whole liver homogenate prepared in phosphate buffered saline (pH 7.4). Triacylglycerols, reduced glutathione (GSH), total protein, and DNA and RNA concentrations were estimated in 20% whole liver homogenate prepared in ice-cold Tris-sucrose buffer (Tris-HCl 50 mmol/L and sucrose 0.25 mol/L, pH 7.4). Aliquots of the latter homogenate were centrifuged at 15 000 rpm for 15 min at 4°C and the supernatants were collected for the determination of superoxide dismutase (SOD), glutathione peroxidase (GPx), and catalase (CAT) activities.

Biochemical assays

Serum conjugated bilirubin and total protein were colorimetrically determined using a commercial assay kit (Greiner Diagnostic GmbH, Baden-Württemberg, Germany) and by the method of Gornall et al. [20], respectively. Electrophoretic quantitation of serum protein fractions (five samples per group) was done on cellulose acetate strips (Helena Biosciences Europe, Genova, Italy) and the bands were visualized with Ponceau S stain and scanned (Cliniscan-3 Densitometer, Helena Laboratories, Beaumont, TX, USA), and then the absolute content for each protein band was automatically calculated. The concentration of triacylglycerols was estimated in the whole liver homogenates by the method of Gottfried and Rosenberg [21]. Hepatic lipid peroxides were assessed as thiobarbituric reactive substances [22] using MDA as a standard with an extinction coefficient of $1.53 \times 10^5 \text{ mol/L}^{-1}/\text{cm}^{-1}$ [23]. The GSH and hydroxyproline contents were estimated in the whole liver homogenate by the methods of Beutler et al. [24] and Neuman and Logan [25], respectively. Total protein concentration was estimated in the whole tissue homogenates and their cytosolic fractions by the dye binding method of Bradford [26]. Total DNA and RNA concentrations were extracted from the whole tissue homogenate by 5% perchloric acid according to the method of Schneider [27] and then determined colorimetrically by the diphenylamine [28] and orcinol [29] methods, respectively. The protein/DNA and RNA/DNA ratios were calculated.

Enzyme assays

Serum alanine and aspartate aminotransferase (ALT and AST, respectively) activities were determined by the colorimetric method of Reitman and Frankel [30]. Alkaline phosphatase (ALP) activity was determined by the colorimetric method of Kind and King [31]. SOD (EC 1.15.1.1), GPx (EC 1.11.1.9), and CAT (EC 1.11.1.6) were determined in the cytosolic fractions of the liver homogenates using commercial assay kits provided by R&D Systems (Minneapolis, MN, USA) and Bioxytech (Portland, OR, USA). The antioxidant enzyme activities were expressed as units per milligram of protein.

Histologic studies

Fixed liver samples (six per group) were processed to form paraffin cubes, and then thin sections (5 μ m) were cut, stained in hematoxylin and eosin solution, and examined under a light microscope at a magnification of 125 \times to 600 \times . Each slide was examined for the presence of ballooning degeneration, inflammatory cell infiltration, and necrosis of hepatocytes, which were graded on a 4-point scale, where grade 0 (G0) is negative, grade 1 (G1) is up to 33%, grade 2 (G2) is 33% to 66%, and grade 3 (G3) is higher than 66%. The stage of liver fibrosis in each slide was graded with the METAVIR scale, which grades fibrosis on a 5-point scale: F0, no fibrosis; F1, portal fibrosis without septa; F2, portal fibrosis with a few septa; F3, numerous septa without cirrhosis; and F4, cirrhosis [32].

In vitro antioxidant studies

The antioxidant and iron-chelating activities of the sea cucumber mixed extract were determined in cell-free systems. Three doubled dose levels (150–600 μ g/mL) were chosen and compared with synthetic reference standards. The lowest dose was roughly comparable to the approximate drug concentration pharmacologically achievable in the host's serum by the dose 14.40 mg/kg of body weight, which was used in the biochemical studies. The effect of sea cucumber extract in scavenging nitric oxide (NO $^{\cdot}$) and 1,1-diphenyl-2-picrylhydrazyl hydrate (DPPH $^{\cdot}$) radicals were assessed by the methods of Garrat [33] and Liyana-Pathiranan and Shahidi [34], respectively. Ascorbic acid (200 μ g/mL), *tert*-butyl-hydroquinone, and butylated hydroxyanisole (600 μ g/mL) were used as reference standards [35,36]. The capacity of the extract for iron chelation was measured by the method of Tang et al. [37] using ethylenediaminetetraacetic acid (100 μ g/mL) as the standard. Inhibition of lipid peroxidation was determined according to the method of Liu and Ng [38] using freshly prepared 25% rat liver homogenate as a source of polyunsaturated fatty acids. The percentage of inhibition of lipid peroxidation was assessed by comparing the absorbance of the extract with that of control (homogenate mixture without the extract).

Statistical analysis

Data were expressed as mean \pm standard deviation. The numbers of survivors and deaths at the end of the experiment were statistically evaluated by the Fisher exact test. Results of biochemical studies were statistically analyzed using one-way analysis of variance. In case of a significant *F* ratio, the post hoc Bonferroni test for multiple comparisons was done. In histologic studies, Kruskal–Wallis and Mann–Whitney rank-sum tests were used to detect the significance between groups, respectively. All statistics were done using SPSS 17 for Windows (SPSS, Inc., Chicago, IL, USA). Differences were considered statistically significant at *P* < 0.05.

Results

Metabolic and phenolic compounds in sea cucumber extract

The concentrations of total protein, lipid, and carbohydrate in the sea cucumber mixed extract were found to be 290, 27.36, and 18.7 mg/g of dry weight extract, respectively, which were equivalent to 2.90, 0.27, and 0.19 mg/g of wet body weight. Analysis of the extract by high-performance liquid chromatography revealed the presence of nine non-volatile phenolic compounds, of which only three were unidentified under the adopted conditions. Chlorogenic acid was the major component (92.86%), whereas ascorbic acid (0.067%) was the minor component. Other components, such as pyrogallol (2.99%), rutin (1.83%), coumaric acid (1.55%), and catechin (0.51%), were also detected (Table 1).

Table 1

High-performance liquid chromatographic analysis of sea cucumber mixed extract

| Peak no. | t _R (min) | Concentration (%) | Compound |
|----------|----------------------|-------------------|------------------|
| 1 | 3.331 | 92.86 | chlorogenic acid |
| 2 | 3.382 | 2.99 | pyrogallol |
| 3 | 3.713 | 1.83 | rutin |
| 4 | 3.966 | 0.067 | ascorbic acid |
| 5 | 4.053 | 0.097 | unidentified |
| 6 | 4.581 | 0.51 | catechin |
| 7 | 5.165 | 0.046 | unidentified |
| 8 | 5.38 | 1.55 | coumaric acid |
| 9 | 6.477 | 0.039 | unidentified |

t_R, retention time

Effects of sea cucumber extract and/or TAA on body weight, some body organ weights, and survival rate

A gradual increase in the body weight of NC rats and those given sea cucumber extract was recorded, which amounted to 15.24% and 18.67%, respectively, at the end of the experiment compared with their initial body weights. However, a sharp decrease was recorded in the body weight of TAA-intoxicated rats (21.03%), which was substantially modified in the protective group (4.34%; Fig. 1). TAA intoxication (TAA group) caused the death of two rats in weeks 1, 2, 3, and 5 and one rat in weeks 4, 6, and 7, attaining a survival rate of 45% (9 of 20 rats) at the end of the treatment period (*P* < 0.05 versus NC; Table 2). In the protective group (Ex + TAA), two mortalities in weeks 2, 6, and 7 and one mortality in week 3 were recorded, attaining a survival rate of 65% (13 of 20 rats) at the end of the experiment (*P* > 0.05 versus NC; Table 2).

Oral administration of sea cucumber extract to normal rats caused significant decreases in the absolute weights of the liver, heart, kidneys, and spleen (29.09%, 23.08%, 22.56%, and 22.22%, respectively), whereas their relative weights were insignificantly changed compared with NC rats. TAA intoxication caused significant increases in the absolute and relative weights of the liver, kidneys, and spleen (17.39% and 69.9%, 27.82% and 87.76%, 61.62% and 129.73%, respectively) and in the relative heart weight (40.88%), whereas its absolute weight was significantly decreased compared with NC rats. The coadministration of sea cucumber extract and TAA intoxication significantly decreased the wet weights of the liver (14.54%), heart (23.08%), and spleen (27.27%), whereas the kidneys were not affected. In addition, it

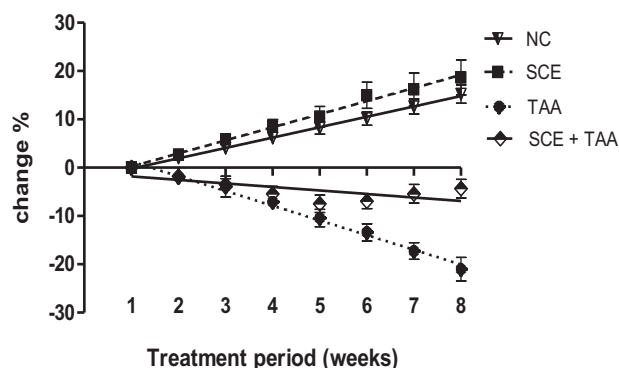


Fig. 1. Changes in the body weight gain of rats (expressed as percentage) in the different treatment groups throughout the experimental period (8 wk) compared with their initial body weights. Each point represents mean \pm SD of 9 to 20 rats. NC, normal control; SCE, sea cucumber extract; TAA, thioacetamide.

Table 2
Percentage of survival of rats at the end of treatment in different groups

| Groups | 0 wk | 8 wk | |
|----------|------|---------------|------------|
| | | Survivors (%) | Deaths (%) |
| NC | 10 | 10 (100%) | 0.0 (0%) |
| Ex | 12 | 12 (100%) | 0.0 (0%) |
| TAA | 20 | 9.0 (45%)* | 11 (65%) |
| Ex + TAA | 20 | 13 (65%) | 7.0 (35%) |
| Total | 62 | 44 | 18 |

Ex, sea cucumber extract; NC, normal control; TAA, thioacetamide

* Significantly different at $P < 0.05$ versus NC.

normalized the relative weights of all organs except the liver, which was slightly but significantly increased (15.66%) compared with NC rats (Table 3).

Effects of sea cucumber extract and/or TAA on liver function tests

The oral administration of sea cucumber mixed extract to normal rats caused non-significant changes in serum conjugated bilirubin level, ALT, AST, and ALP activities, and the AST/ALT ratio compared with NC rats. In contrast, TAA intoxication caused dramatic increases in serum conjugated bilirubin (112.5%), ALT (168.53%), AST (493.91%), and ALP (272.62%) activities and the AST/ALT ratio (140.43%) compared with NC rats. Subchronic administration of sea cucumber extract and TAA intoxication normalized serum conjugated bilirubin levels, ALT, AST, and the AST/ALT ratio, whereas a slight but significant increase in ALP activity (27.52%) was recorded (Table 4).

Effects of sea cucumber extract and/or TAA on serum total protein and its fractions

The oral treatment of normal rats with sea cucumber extract caused non-significant changes in serum total protein level and its fractions compared with normal controls. In contrast, TAA intoxication produced significant decreases in serum total protein (31.04%), albumin (27.78%), and α_1 - (41.67%), α_2 - (40%), β - (30.38%), and γ - (33.87%) globulin concentrations compared with NC rats. The coadministration of sea cucumber extract and TAA to rats restored serum protein fractions to normal levels. The ratio of albumin to globulin was insignificantly changed in all treatment modalities (Table 5).

Table 3
Effects of sea cucumber mixed extract and/or thioacetamide on the wet and relative weights ($\times 10^{-3}$) of some body organs in rats*

| Groups | Liver | | Heart | | Kidneys | | Spleen | |
|---------------|------------------------------|-------------------------------|------------------------------|------------------------------|------------------------------|------------------------------|-------------------------------|------------------------------|
| | g | wt/bw | g | wt/bw | g | wt/bw | g | wt/bw |
| NC | | | | | | | | |
| Mean \pm SD | 6.67 \pm 0.55 ^a | 24.65 \pm 0.50 ^a | 0.91 \pm 0.03 ^a | 3.62 \pm 2.00 ^a | 1.33 \pm 0.13 ^a | 4.90 \pm 0.69 ^a | 0.99 \pm 0.07 ^a | 3.70 \pm 0.35 ^a |
| Ex | | | | | | | | |
| Mean \pm SD | 4.73 \pm 0.59 ^b | 25.34 \pm 2.26 ^a | 0.70 \pm 0.09 ^b | 4.30 \pm 1.70 ^a | 1.03 \pm 0.13 ^b | 5.31 \pm 0.55 ^a | 0.77 \pm 0.20 ^{bd} | 4.10 \pm 0.89 ^a |
| Change (%) | -29.09 | 2.80 | -23.08 | 18.78 | -22.56 | 8.37 | -22.22 | 10.81 |
| TAA | | | | | | | | |
| Mean \pm SD | 7.83 \pm 0.47 ^c | 41.88 \pm 3.05 ^b | 0.78 \pm 0.04 ^b | 5.10 \pm 1.50 ^b | 1.70 \pm 0.11 ^c | 9.20 \pm 0.97 ^b | 1.60 \pm 0.16 ^c | 8.50 \pm 0.82 ^b |
| Change (%) | 17.39 | 69.90 | -14.29 | 40.88 | 27.82 | 87.76 | 61.62 | 129.73 |
| Ex + TAA | | | | | | | | |
| Mean \pm SD | 5.70 \pm 0.73 ^d | 28.51 \pm 2.73 ^c | 0.70 \pm 0.10 ^b | 3.90 \pm 1.60 ^a | 1.20 \pm 0.16 ^a | 5.50 \pm 0.53 ^a | 0.72 \pm 0.23 ^d | 3.60 \pm 0.87 ^a |
| Change (%) | -14.54 | 15.66 | -23.08 | 7.73 | -9.77 | 12.24 | -27.27 | -2.70 |
| F ratio | 49.75 | 109.70 | 16.38 | 50.02 | 44.72 | 71.71 | 43.82 | 88.29 |

bw, body weight; Ex, sea cucumber extract; NC, normal control; TAA, thioacetamide; wt, weight

* Data are expressed as mean \pm SD ($n = 9$ –13 rats). Values sharing the same superscripts are not significantly different.

Effects of sea cucumber extract and/or TAA on hepatic GSH, MDA, and antioxidant enzymes

Subchronic administration of sea cucumber extract to normal rats significantly induced hepatic SOD and GPx activities, whereas GSH and MDA concentrations and CAT activity were insignificantly changed compared with NC rats. In contrast, TAA intoxication significantly increased hepatic MDA (278.61%) and GSH (263.01%) concentrations and decreased SOD (96.81%), GPx (69.05%), and CAT (26.07%) activities compared with NC rats. All the foregoing parameters were normalized in the protective group (Table 6).

Effects of sea cucumber extract and/or TAA on hepatic triacylglycerols, hydroxyproline, total protein, and nucleic acid concentrations

The oral treatment of rats with sea cucumber extract did not produce any significant changes in hepatic triacylglycerols, hydroxyproline, total protein, RNA and DNA levels, and protein/DNA and RNA/DNA ratios compared with NC rats. TAA intoxication induced significant increases in hepatic triacylglycerols (208.76%) and hydroxyproline (1890.91%) concentrations and the protein/DNA ratio (31.22%); in contrast, significant decreases were recorded in total protein, RNA, and DNA concentrations (40.34%, 59%, and 54.98%, respectively) compared with the NC rats. All of the aforementioned parameters were normalized in the protective group, except for a slight but significant increase in triacylglycerols level (36.83%). The hepatic RNA/DNA ratio was not changed in any treatment modality (Table 7).

Histologic examination

Histologic examination of liver sections from NC and Ex-treated rats that were stained with hematoxylin and eosin (Fig. 2a, b) showed a normal cellular architecture. In contrast, liver sections of TAA-intoxicated rats showed severe degenerative changes; notably ballooning degeneration (G3), necrosis and infiltration of inflammatory cells (G3), and advanced fibrosis (F3; Tables 8, 9, Fig. 2c–f). Conversely, liver sections of the protective group showed an almost normal pattern with an increased normal hepatocyte parenchyma, decreased development of fibrous septa and lymphocyte infiltration (G0–G2), liver fibrosis (F0–F2), and good recovery from necrosis (G0; Tables 8, 9; Fig. 2g, h).

Table 4
Effects of sea cucumber mixed extract and/or thioacetamide on serum direct bilirubin level, ALT, AST, and ALP activities and AST/ALT ratio in rats*

| Groups | Conjugated bilirubin (mg/dL) | ALT (U/L) | AST (U/L) | ALP (U/L) | AST/ALT ratio |
|------------|------------------------------|----------------------------|-----------------------------|-----------------------------|--------------------------|
| NC | | | | | |
| Mean ± SD | 0.40 ± 0.06 ^a | 33.75 ± 7.44 ^a | 103.13 ± 24.78 ^a | 56.76 ± 4.90 ^a | 3.29 ± 0.53 ^a |
| Ex | | | | | |
| Mean ± SD | 0.35 ± 0.04 ^a | 30 ± 8.86 ^a | 121.88 ± 33.91 ^a | 52.89 ± 4.75 ^a | 3.45 ± 0.86 ^a |
| Change (%) | -12.5 | -11.11 | 18.18 | -6.82 | 4.86 |
| TAA | | | | | |
| Mean ± SD | 0.85 ± 0.06 ^b | 90.63 ± 26.52 ^b | 612.5 ± 88.64 ^b | 211.50 ± 14.27 ^b | 7.91 ± 0.74 ^b |
| Change (%) | 112.5 | 168.53 | 493.91 | 272.62 | 140.43 |
| Ex + TAA | | | | | |
| Mean ± SD | 0.39 ± 0.06 ^a | 40.63 ± 6.23 ^a | 129.64 ± 24.12 ^a | 72.38 ± 7.17 ^c | 3.43 ± 0.86 ^a |
| Change (%) | -2.5 | 20.39 | 25.71 | 27.52 | 4.26 |
| F ratio | 192.01 | 62.70 | 519.30 | 658.87 | 70.66 |

ALP, alkaline phosphatase; ALT, alanine aminotransferase; AST, aspartate aminotransferase; Ex, sea cucumber extract; NC, normal control; TAA, thioacetamide
* Data are expressed as mean ± SD (n = 9–13 rats per group). Values sharing the same superscripts are not significantly different.

Antioxidant activity of sea cucumber extract

The sea cucumber (*H. atra*) extract exhibited a high scavenging activity for NO[•] (93.42% at 600 µg/mL) compared with standard vitamin C (44.7% at 200 µg/mL) and a low scavenging activity for DPPH[•] (16.8–17.01%) at all tested concentrations with respect to strong synthetic antioxidants, butylated hydroxyanisole (84.7% at 600 µg/mL), and *tert*-butyl-hydroquinone (85.3% at 600 µg/mL). For iron chelating activity, the extract showed moderate potential (57% at 600 µg/mL) compared with ethylenediaminetetraacetic acid (100% at 100 µg/mL). The sea cucumber extract showed a dose-dependent inhibition of lipid peroxidation (28.02%, 33.76%, and 36.4% at 150, 300, and 600 µg/mL, respectively; Table 10).

Discussion

In the present study, quantitative analysis of the metabolic compounds in sea cucumber (*H. atra*) mixed extract revealed its higher protein content compared with lipid and carbohydrate. High-performance liquid chromatographic analysis of the phenolic compounds in the sea cucumber mixed extract revealed the presence of nine components. Chlorogenic acid was the major compound, whereas ascorbic acid was the minor compound (Table 1). The main sources of food for sea cucumbers, which are phenolic-rich materials such as phytoplankton and particles derived from degrading marine macro-algae, may account for the presence of the active phenolic compounds in the body wall of sea cucumbers [1]. Polyphenols are primary

antioxidants that are also known as free radical terminators. They react with high-energy lipid radicals, converting them to thermodynamically more stable products. Furthermore, they are excellent hydrogen or electron donors [39]. Chlorogenic acid is one of the most abundant polyphenols in the human diet and has been reported to decrease the incidence of chemical carcinogenesis in several animal models of cancer [40]. Pyrogallol, a catechin compound that generates superoxide anion, has been shown to induce apoptosis in human cancer cell lines [41]. Rutin, a flavonoid, has shown pharmacologic benefits including antitumor, anti-inflammatory, immune-modulating, and hepatoprotective activities [42]. *P*-Coumaric acid is a common dietary phenolic acid widely distributed in plants. Its potent hepatoprotective effect has previously been demonstrated in rats intoxicated with carbon tetrachloride [43], ethanol [44], and lipopolysaccharide [45]. Catechin is a polyphenolic flavonoid-derived compound that possesses a broad range of pharmacologic properties, including an antioxidative effect [46].

In the present study, the hepatoprotective effect of sea cucumber extract was investigated against TAA-induced hepatotoxicity in rats. The establishment of a positive control group was not compelling because the literature contains abundant evidence on natural compounds, such as silymarin, with antioxidant and hepatoprotective activities. TAA is considered a potent hepatotoxin, which is frequently used to produce an experimental model to study the mechanisms involved in the progression of hepatic disease and the impact of various drugs on this progression. Hepatic injury caused by TAA shows lesions similar to those seen in most cases of human liver disease. It

Table 5
Effects of sea cucumber extract and/or thioacetamide on serum total protein and its fractions and albumin/globulin ratio in rats*

| Groups | Total protein (g/dL) | Albumin (g/dL) | Globulins (g/dL) | | | | Albumin/globulin ratio |
|------------|--------------------------|---------------------------|--------------------------|--------------------------|--------------------------|--------------------------|--------------------------|
| | | | α ₁ | α ₂ | β | γ | |
| NC | | | | | | | |
| Mean ± SD | 7.86 ± 0.38 ^a | 3.96 ± 0.68 ^a | 0.48 ± 0.03 ^a | 0.60 ± 0.14 ^a | 1.58 ± 0.16 ^a | 1.24 ± 0.34 ^a | 1.03 ± 0.27 ^a |
| Ex | | | | | | | |
| Mean ± SD | 7.95 ± 0.34 ^a | 4.00 ± 0.33 ^a | 0.48 ± 0.13 ^a | 0.54 ± 0.13 ^a | 1.64 ± 0.21 ^a | 1.20 ± 0.43 ^a | 1.05 ± 0.20 ^a |
| Change (%) | 1.15 | 1.01 | 0 | -10.00 | 3.80 | -3.23 | 1.94 |
| TAA | | | | | | | |
| Mean ± SD | 5.42 ± 0.37 ^b | 2.86 ± 0.61 ^b | 0.28 ± 0.04 ^b | 0.36 ± 0.05 ^b | 1.10 ± 0.14 ^b | 0.82 ± 0.13 ^b | 1.11 ± 0.23 ^a |
| Change (%) | -31.04 | -27.78 | -41.67 | -40.00 | -30.38 | -33.87 | 7.77 |
| Ex + TAA | | | | | | | |
| Mean ± SD | 7.10 ± 0.67 ^a | 3.36 ± 0.41 ^{ab} | 0.46 ± 0.11 ^a | 0.58 ± 0.16 ^a | 1.50 ± 0.23 ^a | 1.20 ± 0.19 ^a | 0.90 ± 0.19 ^a |
| Change (%) | -9.67 | -15.15 | -4.17 | -3.33 | -5.06 | -3.23 | -12.62 |
| F ratio | 31.22 | 5.24 | 6.51 | 3.53 | 8.18 | 6.30 | 0.68 |

Ex, sea cucumber extract; NC, normal control; TAA, thioacetamide

* Data are expressed as mean ± SD (n = 5 rats per group). Values sharing the same superscripts are not significantly different.

Table 6
Effects of sea cucumber extract and/or thioacetamide on hepatic MDA and GSH concentrations and antioxidant enzyme activities in rats*

| Groups | MDA (nmol/g) | GSH (nmol/mg protein) | SOD (U/mg protein) | GPx (mU/mg protein) | CAT (U/mg protein) |
|------------|----------------------------|---------------------------|--------------------------|-----------------------------|------------------------------|
| NC | | | | | |
| Mean ± SD | 31.23 ± 5.20 ^a | 10.30 ± 1.09 ^a | 3.76 ± 0.99 ^a | 432.91 ± 13.17 ^a | 742.83 ± 88.9 ^a |
| Ex | | | | | |
| Mean ± SD | 32.30 ± 2.89 ^a | 9.99 ± 1.25 ^a | 6.25 ± 0.42 ^b | 550.94 ± 53.73 ^b | 799.91 ± 127.7 ^a |
| Change (%) | 3.43 | -3.01 | 66.22 | 27.26 | 7.68 |
| TAA | | | | | |
| Mean ± SD | 118.24 ± 9.42 ^b | 37.39 ± 7.39 ^b | 0.12 ± 0.03 ^c | 134.0 ± 41.36 ^c | 549.17 ± 71.70 ^b |
| Change (%) | 278.61 | 263.01 | -96.81 | -69.05 | -26.07 |
| Ex + TAA | | | | | |
| Mean ± SD | 36.85 ± 6.40 ^a | 11.31 ± 1.22 ^a | 3.72 ± 1.10 ^a | 389.03 ± 47.54 ^a | 731.07 ± 135.40 ^a |
| Change (%) | 17.99 | 9.81 | -1.06 | -10.14 | -1.58 |
| F ratio | 348.73 | 98.28 | 88.72 | 87.98 | 7.91 |

CAT, catalase; Ex, sea cucumber extract; GPx, glutathione peroxidase; GSH, reduced glutathione; MDA, malondialdehyde; NC, normal control; SOD, superoxide dismutase; TAA, thioacetamide

* Data are expressed as mean ± SD ($n = 9-13$ rats per group). Values sharing the same superscripts are not significantly different.

induces cytotoxic injury through a two-step bioactivation, which is mediated by the microsomal cytochrome P450 isozyme E1 and/or flavin-containing monooxygenase systems, to TAA sulfide and further to a reactive metabolite, TAA-S,S-dioxide, which causes lipid peroxidation at the plasma membrane level [47]. A decrease of lipid peroxidation-mediated oxidative stress may be a potential and effective strategy for the prevention and treatment of hepatic failure [48].

Subchronic administration of sea cucumber extract at the implemented dose to normal rats showed no toxic side effects on the host as evident by the insignificant changes in the relative weights of the liver, heart, kidneys, and spleen, favorable growth rate, and survival rate (100%) of the animals (Tables 2, 3, Fig. 1). In contrast, TAA intoxication has shown a dramatic decrease in the percentage of body weight gain, low toll of survival rate (45%), and significant increases in the relative weights of body organs. All these findings were substantially modified in the protective group, represented by a less notable decrease in the percentage of body weight gain compared with their initial body weight, higher survival rate (65%), and normalization of the relative weight of all body organs except for the liver, which was slightly increased (Tables 2, 3, Fig. 1). It is apparent that the toxic side effects of TAA were counterbalanced by the active phenolic compounds in the sea cucumber extract. Coumaric and chlorogenic acids are known to quench oxygen radical formation and to inhibit the formation of inflammatory mediators such as prostaglandins and leukotrienes, which might account for the significant increase of the relative weights of the liver, heart, kidneys, and spleen.

Direct evidence of TAA hepatotoxicity was noted in the occurrence of marked increases in the levels of serum conjugated bilirubin, ALT, AST, and ALP activities, the AST/ALT ratio, and liver triacylglycerols concentration (Tables 4, 7). The dramatic increase in the serum levels of conjugated bilirubin and AST and ALP activities provided evidence of intrahepatic biliary obstruction, which was confirmed by histologic examination of liver sections showing the presence of intense inflammatory cells infiltration (G3), ballooning degeneration (G3), necrosis (G3), and fibrosis (F3; Tables 8, 9). The coadministration of sea cucumber extract and TAA substantially attenuated the hepatotoxic effect of TAA as evident by the normalization of serum bilirubin, ALT and AST activities, and the AST/ALT ratio and the decreases in serum ALP activity and hepatic triacylglycerols content. In addition, examination of liver sections stained with hematoxylin and eosin (six slides) showed slight alterations in the hepatocytes, notably inflammation (G0–G2), ballooning degeneration (G0–G2), fibrosis (F0–F2), and good recovery from necrosis (G0; Tables 8, 9, Fig. 2g, h). The effects of oral and parental administrations of chlorogenic acid on decreasing triacylglycerols in the plasma, liver, and skeletal muscles of animals have been reported previously [49,50].

The concentration of serum proteins can be used as a measurement of liver function, especially when they are compared with proteins that are not produced in the liver, such as the immunoglobulins. TAA intoxication significantly decreased serum total protein, albumin, and α_1 -, α_2 -, and γ -globulin concentrations (Table 5). Comparable results were previously reported and explained [51,52]. A more valuable observation in

Table 7
Effects of sea cucumber extract and/or thioacetamide on hepatic TG, hydroxyproline, total protein, RNA and DNA concentrations, and protein/DNA and RNA/DNA ratios in rats*

| Groups | TG (mg/g) | Hydroxyproline (μ g/mg protein) | Total protein (mg/g) | RNA (mg/g) | DNA (mg/g) | Protein/DNA | RNA/DNA |
|------------|---------------------------|--------------------------------------|-----------------------------|--------------------------|--------------------------|-----------------------------|--------------------------|
| NC | | | | | | | |
| Mean ± SD | 31.96 ± 1.51 ^a | 0.99 ± 0.06 ^a | 175.14 ± 7.52 ^a | 6.22 ± 0.74 ^a | 2.51 ± 0.25 ^a | 71.74 ± 9.52 ^a | 2.48 ± 0.12 ^a |
| Ex | | | | | | | |
| Mean ± SD | 32.22 ± 3.10 ^a | 1.00 ± 0.11 ^a | 170.27 ± 12.20 ^a | 6.00 ± 0.30 ^a | 2.38 ± 0.28 ^a | 72.5 ± 11.21 ^a | 2.55 ± 0.32 ^a |
| Change (%) | 0.81 | 1.01 | -2.78 | -3.54 | -5.18 | 1.06 | 2.82 |
| TAA | | | | | | | |
| Mean ± SD | 98.68 ± 5.90 ^b | 19.71 ± 3.52 ^b | 104.48 ± 12.42 ^b | 2.55 ± 0.5 ^b | 1.13 ± 0.13 ^b | 94.14 ± 18.17 ^b | 2.29 ± 0.53 ^a |
| Change (%) | 208.76 | 1890.91 | -40.34 | -59.00 | -54.98 | 31.22 | -7.66 |
| Ex + TAA | | | | | | | |
| Mean ± SD | 43.73 ± 6.53 ^c | 1.19 ± 0.07 ^a | 166.54 ± 10.25 ^a | 5.57 ± 0.82 ^a | 2.11 ± 0.40 ^a | 81.26 ± 15.73 ^{ab} | 2.66 ± 0.39 ^a |
| Change (%) | 36.83 | 20.20 | -4.91 | -10.45 | -15.94 | 13.27 | 7.26 |
| F ratio | 364.48 | 224.73 | 76.20 | 59.95 | 40.06 | 4.38 | 1.39 |

Ex, sea cucumber extract; NC, normal control; TAA, thioacetamide; TG, triacylglycerols

* Data are expressed as mean ± SD ($n = 9-13$ rats per group). Values sharing the same superscripts are not significantly different.

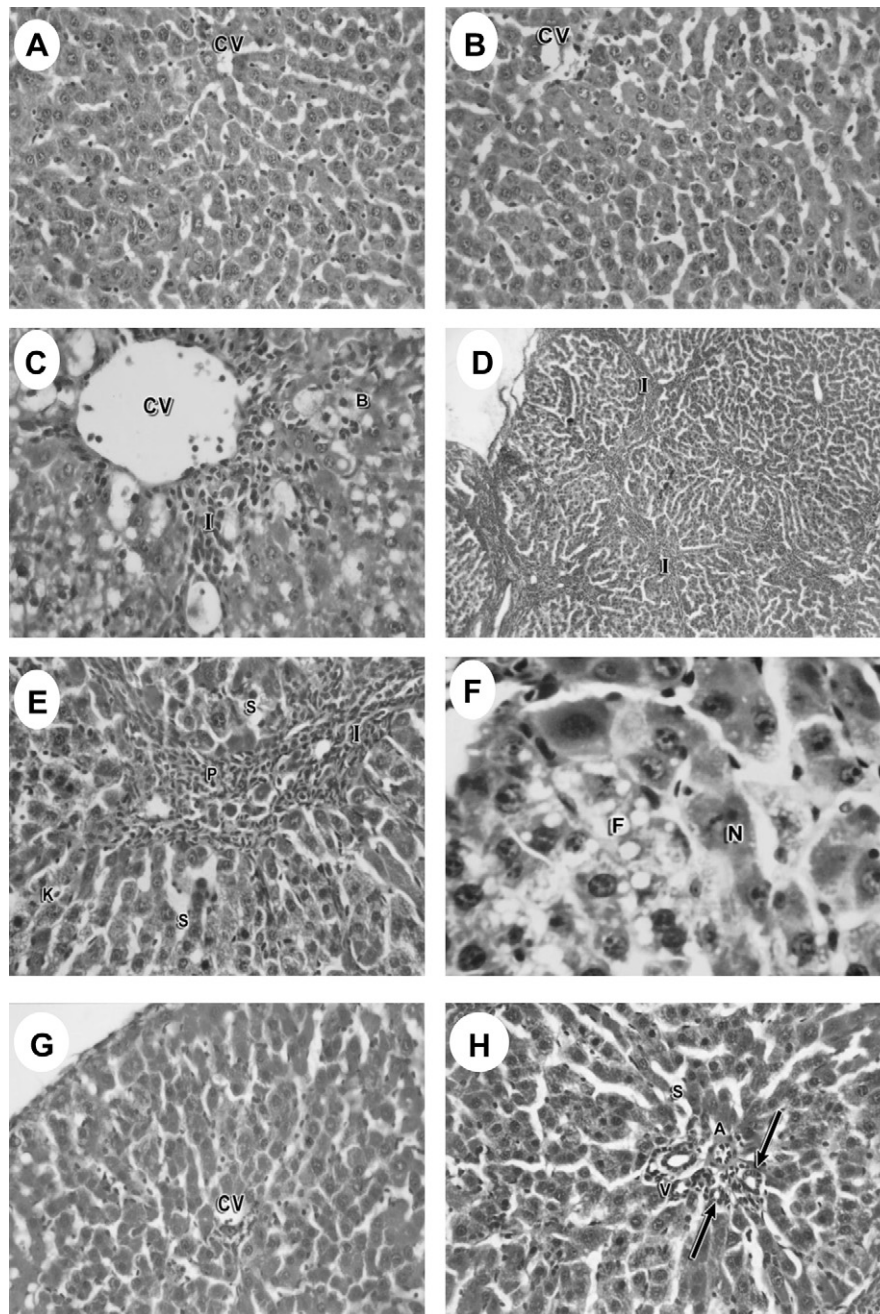


Fig. 2. Photomicrographs of liver sections stained with hematoxylin and eosin from (A) normal rats and (B) rats treated with sea cucumber extract show cords of hepatocytes radiating from the central vein and separated by blood sinusoids (magnification 400 \times). Liver sections of thioacetamide-intoxicated rats show (C) a dilated central vein, ballooning of some hepatocytes, inflammatory cells infiltration (magnification 125 \times), (D) numerous connective tissue strands invaded by inflammatory cells (magnification 125 \times), (E) dilated blood sinusoids, portal tract area, Kupffer cells, numerous connective tissue strands invaded by inflammatory cells (magnification 400 \times), and (F) fatty change and necrotic cells (magnification 600 \times). Liver sections of the protective group show (G) normal-appearing cords of hepatocytes radiating from the central vein (magnification 400 \times) and (H) portal vein, portal artery, branches of portal ducts more or less similar to normal controls (arrow), and dilated blood sinusoids (magnification 400 \times). A, portal artery; B, ballooning of hepatocytes; CV, central vein; F, fatty change; I, inflammatory cells; K, Kupffer cells; N, necrotic cells; P, portal tract area; S, sinusoids; V, portal vein.

our study is the normalization of serum total protein and its fractions in rats treated with sea cucumber extract and TAA intoxication. We suggest that normalization of serum γ -globulin by sea cucumber extract might be due to its content of chlorogenic and coumaric acids, which warrants further investigation. These phenolic acids have been reported to induce phase II detoxifying enzymes, which suppress TAA-active metabolites from inducing immune suppression [40,53].

The measurement of antioxidant enzymes activity is an appropriate indirect way to assess the status of antioxidant defense and, in addition to the estimation of MDA, a byproduct of peroxidation of biological membrane polyunsaturated fatty acids, is used as an indicator of oxidative stress [54]. Subchronic administration of sea cucumber extract to normal rats increased hepatic SOD and GPx activities (Table 6). In accord with our findings, Pingzhang et al. [55] demonstrated that treatment of

Table 8

Degrees of inflammatory cells infiltration, ballooning of hepatocytes and liver necrosis in the different studied groups*

| Groups | Inflammatory cells infiltration | | | | Ballooning degeneration | | | | Necrosis | | | |
|----------|---------------------------------|-----|-----|-----|-------------------------|-----|-----|-----|------------------|-----|-----|-----|
| | G0 | G1 | G2 | G3 | G0 | G1 | G2 | G3 | G0 | G1 | G2 | G3 |
| NC | 6/6 ^a | 0/6 | 0/6 | 0/6 | 6/6 ^a | 0/6 | 0/6 | 0/6 | 6/6 ^a | 0/6 | 0/6 | 0/6 |
| Ex | 6/6 ^a | 0/6 | 0/6 | 0/6 | 6/6 ^a | 0/6 | 0/6 | 0/6 | 6/6 ^a | 0/6 | 0/6 | 0/6 |
| TAA | 0/6 ^b | 0/6 | 0/6 | 6/6 | 0/6 ^b | 0/6 | 0/6 | 6/6 | 0/6 ^b | 0/6 | 0/6 | 6/6 |
| Ex + TAA | 2/6 ^c | 2/6 | 2/6 | 0/6 | 2/6 ^c | 2/6 | 2/6 | 0/6 | 6/6 ^a | 0/6 | 0/6 | 0/6 |

Ex, sea cucumber extract; G0, negative; G1, $\leq 33\%$; G2, 33% to 66%; G3, $>66\%$; NC, normal control; TAA, thioacetamide

* Lymphocyte infiltration, ballooning degeneration, and necrosis of hepatocytes were examined in six slides per group and graded by a 4-point scale (G0–G3). Values sharing the same superscripts are not significantly different.

mice with catechin increases SOD activity in the large intestine. Yeh and Yen [53] reported that administration of coumaric acid to male Sprague–Dawley rats significantly increases hepatic SOD, GPx, and CAT activities compared with normal controls. To support our biochemical findings, *in vitro* antioxidant studies on the sea cucumber mixed extract were designed according to previous relevant studies [34–36,38,56] and showed a substantial scavenging potential for NO[•] and a weak scavenging potential for DPPH[•] compared with reference standards (Table 10). The weak inhibitory potential to scavenge DPPH[•] could be attributed to its pyrogallol content, which acts as a superoxide anion generator. Furthermore, a moderate iron-chelating potential and a dose-dependent inhibition of lipid peroxidation of the sea cucumber extract have been recorded. Iron is known as a pro-oxidant because of its high reactivity among transition metals. The effective iron chelators may afford protection against oxidative damage by removing Fe²⁺ that may otherwise participate in OH[•] generation and thus lipid peroxidation [57].

The TAA intoxication induced an intense oxidative stress as evident by the increased hepatic MDA and GSH levels and, in contrast, decreased liver antioxidant enzyme activities compared with normal controls (Table 6). Comparable findings have been reported previously [58,59]. However, the literature contains controversial results on the effect of TAA intoxication on the GSH level. Lu et al. [60] reported that the injection of rats with TAA (50 mg · kg⁻¹ · d⁻¹ intraperitoneally for 3 wk) increases hepatic γ -glutamylcysteine synthetase (GCS) subunit expression and GCS activity, whereas GSH level remains unchanged despite the significant oxidative stress as demonstrated by the increased hepatic MDA level. The investigators attributed the induction of GCS activity to protect the hepatic GSH level from being decreased by TAA intoxication. Also, Oliver et al. [61] affirmed that mice that received a single injection of TAA (125 mg/kg of body weight) showed a significant decrease in hepatic GSH level after 12 h, which rebounded to the control level within 24 h. The investigators ascribed the normalization to the increased expression and activity of GCS and GSH

Table 9

Stage of fibrosis in different studied groups*

| Groups | F0 | F1 | F2 | F3 | F4 |
|----------|------------------|-----|-----|-----|-----|
| NC | 6/6 ^a | 0/6 | 0/6 | 0/6 | 0/6 |
| Ex | 6/6 ^a | 0/6 | 0/6 | 0/6 | 0/6 |
| TAA | 0/6 ^b | 0/6 | 0/6 | 6/6 | 0/6 |
| Ex + TAA | 2/6 ^c | 2/6 | 2/6 | 0/6 | 0/6 |

Ex, sea cucumber extract; F0, no fibrosis; F1, portal fibrosis without septa; F2, portal fibrosis with a few septa; F3, numerous septa without cirrhosis; F4, cirrhosis; NC, normal control; TAA, thioacetamide

* The stage of liver fibrosis was examined in six slides per group and graded by a 5-point scale (F0–F4). Values sharing the same superscripts are not significantly different.

synthetase, which are the two key enzymes involved in the synthesis of GSH. The impact of TAA-induced oxidative stress was nullified in the protective group as evident by the normalization of the hepatic GSH level and antioxidant enzyme activity.

Liver fibrosis involves abnormal synthesis and the accumulation of extracellular matrix proteins, in particular collagen, in the liver parenchyma by activated hepatic stellate cells [62]. Hydroxyproline is an amino acid unique to all collagens and its level reflects the amount of collagen present and therefore can be used to determine the extent of fibrosis [63]. TAA intoxication caused a dramatic increase in hepatic hydroxyproline content compared with normal controls, which was supported by the presence of fibrosis (F3) and numerous connective tissue strands invaded by inflammatory cells (Tables 7, 9, Fig. 2d, e). Parallel findings have been reported previously [64,65]. The coadministration of sea cucumber extract and TAA intoxication normalized the hepatic hydroxyproline content and decreased the liver fibrotic pattern (F0–F2; Tables 7, 9, Fig. 2g, h). The hepatoprotective activity of the sea cucumber extract may be due to its content of pyrogallol (a superoxide generator) that elicited an endogenous antioxidant defense system of the body (SOD and GPx) and to other polyphenolic compounds, which have a high scavenging activity for free radicals and active oxygen species produced by TAA intoxication, thus suppressing hepatic stellate cells activation, on the one hand, and inhibiting lipid peroxidation, on the other, which otherwise activate hepatic stellate cells. Also, the effect of polyphenols on the suppression of free radical generating systems (reduced nicotinamide adenine dinucleotide phosphate and cytochrome P450) as evident by the inhibition of

Table 10Effect of sea cucumber mixed extract on scavenging NO[•] and DPPH[•], iron chelation, and inhibition of lipid peroxidation*

| Dose | NO [•] scavenging activity (%) | DPPH [•] radical scavenging activity (%) | Fe ²⁺ chelating activity (%) | Inhibition of lipid peroxidation (%) |
|----------------------------|---|---|---|--------------------------------------|
| Sea cucumber | | | | |
| 150 μ g/mL | 85.5 | 16.8 | 42.7 | 28.02 |
| 300 μ g/mL | 86.8 | 16.8 | 48.8 | 33.76 |
| 600 μ g/mL | 93.42 | 17.01 | 57 | 36.4 |
| Standards | | | | |
| Vitamin C (200 μ g/mL) | 44.7 | — | — | — |
| EDTA (100 μ g/mL) | — | — | 100 | — |
| BHA (600 μ g/mL) | — | 84.7 | — | — |
| TBHQ (600 μ g/mL) | — | 85.3 | — | — |

BHA, butylated hydroxyanisole; DPPH[•], 1,1-diphenyl-2-picrylhydrazyl hydrate radical; EDTA, ethylenediaminetetraacetic acid; NO[•], nitric oxide radical; TBHQ, *tert*-butyl-hydroquinone

* Experiments were carried out in duplicate.

lipid peroxidation in vitro and decreased MDA concentration in vivo could be considered. In addition, we do not believe that the obtained results are presumably due to an attenuation of the hepatotoxic effect of TAA attained by its direct reaction with the phenolic compounds of the extract because each was given to the rats by different routes and at different times and frequencies. However, this assumption warrants further investigation.

The human body contains many molecules (lipids, DNA, protein, vitamins, and carbohydrates) that are susceptible to attack by reactive oxygen species, causing many human diseases. Antioxidants inhibit lipid peroxidation but may not protect other molecules, such as DNA and protein, against oxidative damage. In the present study, the TAA-induced oxidative stress caused significant decreases in liver DNA, RNA, and total protein concentrations, with no significant changes in the RNA/DNA ratio, which indicates that RNA synthesis per cell was not affected. The significant increase of the protein/DNA ratio suggests that reactive oxygen species produced by TAA intoxication caused tissue DNA oxidative damage, which in turn stimulated the unaffected hepatocytes to increase protein synthesis (Table 7). However, the significant decrease in hepatic total protein concentration might be due to hypertrophy of the liver, a smaller number of functioning hepatocytes owing to fibrosis, and fatty liver. It has been reported that increased permeability originating from the lipid peroxidation of endoplasmic reticulum membrane contributes to the increase in water content of the liver (hypertrophy) and the formation of inflammatory mediators such as prostaglandins and leukotrienes [66,67]. In the protective group, hepatic total protein, DNA, and RNA contents and the protein/DNA ratio were normalized. Such protection is suggested to be afforded by the active phenolic compounds in the sea cucumber extract, which protects the nucleic acids from damage and/or enhance the repair mechanism. Huang et al. [68] reported that treatment of murine microglia cells with catechin 0.5 mmol/L after a 1-h exposure to *tert*-butyl hydroperoxide 0.3 mmol/L significantly increased the expression of poly(ADP-ribose)polymerase to protect murine microglia cells from DNA damage. Also, Guglielmi et al. [69] affirmed that coumaric acid effectively decreases DNA oxidative damage in rat colonic mucosa.

Conclusions

Sea cucumber mixed extract exhibited significant hepatoprotective activity against TAA-induced liver fibrosis in rats, demonstrated by an amelioration of liver function tests and substantial improvement in the hepatocellular architecture. The hepatoprotection is due mainly to its content; namely, active phenolic compounds with antioxidant and chelating activities, which enhance the endogenous antioxidant defense system.

References

- [1] Althunibat OS, Hashim RB, Taher M, Daud JM, Ikeda M, Zali I. *In vitro* antioxidant and antiproliferative activities of three Malaysian sea cucumber species. *Eur J Sci Res* 2009;37:376–87.
- [2] Sugawara T, Zaima N, Yamamoto A, Sakai S, Noguchi R, Hirata T. Isolation of sphingoid bases of sea cucumber cerebroside and their cytotoxicity against human colon cancer cells. *Biosci Biotechnol Biochem* 2006;70:2906–12.
- [3] Ridzwan BH. Sea cucumber: the Malaysian heritage. Kuala Lumpur, Malaysia: Research Centre, IJUM; 2007.
- [4] Hamel JF, Mercier A. Synchronous gamete maturation and reliable spawning induction method in holothurians. In: Lovatelli A, Conand C,

Purcell S, Uthicke S, Hamel JF, Mercier A, editors. *Advances in sea cucumber aquaculture and management*. FAO fisheries technical reports no. 463. Rome: FAO; 2004. p. 359–72.

- [5] Darah I, Stheesh N, Ibrahim CO. Growth inhibition of dermatophytes by *atra*-toxins of *Holothuria atra*. *Biosci Penang* 1995;6:40–8.
- [6] Herencia F, Ubeda A, Ferrandiz ML, Terenico MC, Alcaraz MJ, Garcia-Carrascosa M, et al. Anti-inflammatory activity in mice of extracts from Mediterranean marine invertebrates. *Life Sci* 1998;62:PL115–20.
- [7] Ogushi M, Yoshie-Stark M, Suzuki T. Cytostatic activity of hot water extracts from the sea cucumber in Caco-2. *Food Sci Technol Res* 2005;11:202–6.
- [8] Fouda MM, Hellal AM. Key to the Ophiuroidea (echinodermata) from the Red Sea. *J Egypt Germ Soc Zool* 1991;5:243–65.
- [9] Hassan M. Taxonomical and biochemical studies on some species of class holothuroidea (Echinodermata) from the Red Sea. PhD thesis. Ismailia, Egypt: Faculty of Science, Suez Canal University; 2001.
- [10] Zaki MA. Effects of the crude toxin of sea cucumbers *Holothuria atra* on some hematological and biochemical parameters in rats. *Egypt J Nat Toxins* 2005;2:71–86.
- [11] Kadiiska MB, Gladen BC, Baird DD, Dikalova AE, Sohal RS, Hatch GE, et al. Biomarkers of oxidative stress study: are plasma antioxidants markers of CCl₄ poisoning? *Free Radic Biol Med* 2000;28:838–45.
- [12] Lima CF, Fernandes-Ferreira M, Pereira-Wilson C. Phenolic compounds protect HepG2 cells from oxidative damage: relevance of glutathione levels. *Life Sci* 2006;79:2056–68.
- [13] Kong AN, Owuor E, Yu R, Hebbard V, Chen C, Hu R, et al. Induction of xenobiotic enzymes by the MAP kinase pathway and the antioxidant or electrophile response element (ARE/EpRE). *Drug Metab Rev* 2001;33:255–71.
- [14] Haug T, Kjuul AK, Styrvold OB, Sandsdalen E, Olsen ØM, Stensvag K. Antibacterial activity in *Strongylocentrotus droebachiensis* (Echinoidea), *Cucumaria frondosa* (Holothuroidea), and *Asterias rubens* (Asteroidea). *J Invertebr Pathol* 2002;81:94–102.
- [15] Lowry O, Rosenbrough N, Farr A, Randall R. Protein measurement with Folin phenol reagent. *J Biol Chem* 1951;193:265–70.
- [16] Dubois M, Gilles KA, Hamilton JK, Roberts PA, Smith F. Colorimetric method for determination of sugars and related substances. *Anal Chem* 1956;28:350–6.
- [17] Knight JA, Anderson S, Rawle JM. Chemical basis of the sulfo-phosphovanillin reaction for estimating total serum lipids. *Clin Chem* 1972;18:199–202.
- [18] Toyama T, Nakamura H, Harano Y, Yamauchi N, Morita A, Kirishima T, et al. PPAR α ligands activate antioxidant enzymes and suppress hepatic fibrosis in rats. *Biochem Biophys Res Commun* 2004;324:697–704.
- [19] Feron VJ, de Groot AP, Spanjers MT, Til HP. An evaluation of the criterion "organ weight" under conditions of growth retardation. *Food Cosmet Toxicol* 1973;11:85–94.
- [20] Gornall AG, Bardawill CJ, David MM. Determination of serum proteins by means of the biuret reaction. *J Biol Chem* 1949;177:751–66.
- [21] Gottfried SP, Rosenberg B. Improved manual spectrophotometric procedure for determination of serum triglycerides. *Clin Chem* 1973;19:1077–8.
- [22] Esterbauer H, Cheesman KH. Determination of aldehyde lipid peroxidation products: malondialdehyde and 4-hydroxynonenal. *Method Enzymol* 1990;186:407–10.
- [23] Wills ED. Lipid peroxide formation in microsomes, general considerations. *J Biochem* 1969;113:315–27.
- [24] Beutler E, Duron O, Kelly BM. Improved method for the determination of blood glutathione. *J Lab Clin Med* 1963;61:882–8.
- [25] Neuman RE, Logan MA. Determination of hydroxyproline. *J Biol Chem* 1949;184:299–306.
- [26] Bradford MM. A rapid and sensitive method for the quantitation of microgram quantities of protein utilizing the principle of protein dye binding. *Anal Biochem* 1976;72:248–54.
- [27] Schneider WC. Phosphorus compounds in animal tissues. 1. Extraction and estimation of deoxyribose nucleic acid and of ribose nucleic acid. *J Biol Chem* 1945;161:293–303.
- [28] Dische Z, Schwartz K. Estimation of nucleic acids. In: Glick D, editor. *Methods of biochemical analysis*. New York: Interscience Publishers; 1954. p. 299.
- [29] Dische Z. Determination of pentoses. In: Colouirck SP, Kaplan NO, editors. *Methods in enzymology*. New York: Academic Press; 1957. p. 88.
- [30] Reitman S, Frankel S. A colorimetric method for the determination of serum glutamic oxaloacetic and glutamic pyruvic transaminases. *Am J Clin Pathol* 1957;28:56–63.
- [31] Kind PRN, King EJ. Estimation of plasma phosphatase by determination of hydrolyzed phenol with antipyrine. *J Clin Pathol* 1954;7:322–6.
- [32] Cheung PY, Zhang Q, Zhang YO, Bai GR, Lin MCM, Chan B, et al. Effect of Weijia on carbon tetrachloride induced chronic liver injury. *World J Gastroenterol* 2006;12:1912–7.
- [33] Garrat DC. *The quantitative analysis of drugs*, Volume 3. Tokyo, Japan: Chapman and Hall Ltd.; 1964. p 456–8.
- [34] Liyana-Pathiranan CM, Shahidi F. Antioxidant activity of commercial soft and hard wheat (*Triticum aestivum* L.) as affected by gastric pH conditions. *J Agric Food Chem* 2005;53:2433–40.

- [35] Qureshi MN, Kuchekar BS, Logade NA, Haleem MA. *In-vitro* antioxidant and *in-vivo* hepatoprotective activity of *Leucas ciliata* leaves. *Rec Nat Prod* 2010;4:124–30.
- [36] Yen GC, Chang YC, Su SW. Antioxidant activity and active compounds of rice koji fermented with *Aspergillus candidus*. *Food Chem* 2003;83:49–54.
- [37] Tang SZ, Kerry JP, Sheehan D, Buckley DJ. Antioxidative mechanism of tea catechins in chicken meat systems. *Food Chem* 2002;76:45–51.
- [38] Liu F, Ng TB. Antioxidative and free radical scavenging activities of selected medicinal herbs. *Life Sci* 2000;66:725–35.
- [39] Gordon MH. The mechanism of antioxidant action *in vitro*. In: Huson BJF, editor. *Food antioxidants*. London: Elsevier; 1990. p. 1.
- [40] Feng R, Lu Y, Bowman LL, Qian Y, Castranova V, Ding M. Inhibition of activator protein-1, NF- κ B, and MAPKs and induction of phase 2 detoxifying enzyme activity by chlorogenic acid. *J Biol Chem* 2005;280:27888–95.
- [41] Yang CJ, Wang CS, Hung JY, Huang HW, Chia YC, Wang PH, et al. Pyrogallol induces G2-M arrest in human lung cancer cells and inhibits tumor growth in an animal model. *Lung Cancer* 2009;66:162–8.
- [42] Ahmed MM, Zaki NI. Assessment the ameliorative effect of pomegranate and rutin on chlorpyrifos-ethyl-induced oxidative stress in rats. *Nat Sci* 2009;7:49–61.
- [43] Perez-Alvarez V, Bobadilla RA, Muriel P. Structure-hepatoprotective activity relationship of 3,4-dihydroxy cinnamic acid (caffeic acid) derivatives. *J Appl Toxicol* 2001;21:527–31.
- [44] Lee SJ, An SM, Mun GI, Lee SJ, Park KM, Park SH, et al. Protective effect of *sasa quepaertensis* and *p-coumaric acid* on ethanol-induced hepatotoxicity in mice. *J Appl Biol Chem* 2008;51:148–54.
- [45] Xu Y, Chen J, Yu X, Tao W, Jiang F, Yin Z, et al. Protective effects of chlorogenic acid on acute hepatotoxicity induced by lipopolysaccharide in mice. *Inflamm Res* 2010;59:871–7.
- [46] Maeda K, Kuzuya M, Cheng XW, Asai T, Kanda S, Tamaya-Mori N, et al. Green tea catechins inhibit the cultured smooth muscle cell invasion through the basement barrier. *Atherosclerosis* 2003;166:23–30.
- [47] Hessien M, El-Sharkawi I, El-Barbary A, Beltagy DM. Regression of thioacetamide, alcohol and schistosomiasis induced liver fibrosis in mice by silymarin. *Turk J Biochem* 2008;33:131–7.
- [48] Tsuchiya D, Hong S, Matsumori Y, Shiina H, Kayama T, Swanson RA, et al. Overexpression of rat heat shock protein 70 is associated with reduction of early mitochondrial cytochrome c release and subsequent DNA fragmentation after permanent focal ischemia. *J Cereb Blood Flow Metab* 2003;23:718–27.
- [49] Rodriguez de Sotillo DV, Hadley M. Chlorogenic acid modifies plasma and liver concentrations of cholesterol, triacylglycerol, and minerals in (fa/fa) Zucker rats. *J Nutr Biochem* 2002;13:717–26.
- [50] Zhang LT, Chang CQ, Liu Y, Chen ZM. Effect of chlorogenic acid on disordered glucose and lipid metabolism in db/db mice and its mechanism. *Zhongguo Yi Xue Ke Xue Yuan Xue Bao* 2011;33:281–6.
- [51] Lee JW, Shin KD, Lee M, Kim EJ, Han SS, Han MY, et al. Role of metabolism by flavin containing monooxygenase in thioacetamide-induced immunosuppression. *Toxicol Lett* 2003;136:163–72.
- [52] Kumar G, Banu GS, Pappa PV, Sundararajan M, Pandian M. Hepatoprotective activity of *Trianthema portulacastrum* L. against paracetamol and thioacetamide intoxication in albino rats. *J Ethnopharmacol* 2004;92:37–40.
- [53] Yeh CT, Yen GC. Induction of hepatic antioxidant enzymes by phenolic acids in rats is accompanied by increased levels of multidrug resistance-associated protein 3 mRNA expression. *J Nutr* 2006;136:11–5.
- [54] Vaca CE, Wilhelm J, Harms-Ringdahl M. Interaction of lipid peroxidation product with DNA, a review. *Mutat Res Genet Toxicol* 1988;195:137–49.
- [55] Pingzhang Y, Jinying Z, Shujun C, Hara Y, Qingfan Z, Zhengguo L. Experimental studies of the inhibitory effects of green tea catechin on mice large intestinal cancers induced by 1,2-dimethylhydrazine. *Cancer Lett* 2004;2:33–8.
- [56] Esmat AY, Said MM, Hamdy GM, Soliman AA, Khalil SA. *In vivo* and *in vitro* studies on the antioxidant activity of aloin compared to doxorubicin in rats. *Drug Dev Res* 2012;73:154–65.
- [57] Simunek T, Sterba M, Popelova O, Adamcova M, Hrdina R, Gersl V. Anthracycline-induced cardiotoxicity: overview of studies examining the roles of oxidative stress and free cellular iron. *Pharmacol Rep* 2009;61:154–71.
- [58] Diez-Fernandez C, Sanz N, Alvarez AM, Zaragoza A, Cascales M. Influence of aminoguanidine on parameters of liver injury and regeneration induced in rats by a necrogenic dose of thioacetamide. *Br J Pharmacol* 1998;125:102–8.
- [59] Najmi AK, Pillai KK, Pal SN, Akhtar M, Aqil M, Sharma M. Effect of L-ornithine L-aspartate against thioacetamide-induced hepatic damage in rats. *Indian J Pharmacol* 2011;42:384–7.
- [60] Lu SC, Huang Z, Yang H, Tsukamoto H. Effect of thioacetamide on the hepatic expression of γ -glutamylcysteine synthetase subunits in the rat. *Toxicol Appl Pharmacol* 1999;159:161–8.
- [61] Oliver JR, Jiang S, Cherian MG. Augmented hepatic injury followed by impaired regeneration in metallothionein-I/II knockout mice after treatment with thioacetamide. *Toxicol Appl Pharmacol* 2006;210:190–9.
- [62] Friedman SL. Liver fibrosis—from bench to bedside. *J Hepatol* 2003;38(suppl 1):38–53.
- [63] Tsukada S, Parsons CJ, Rippe RA. Mechanisms of liver fibrosis. *Clin Chim Acta* 2006;364:33–60.
- [64] Geng J, Peng W, Huang Y, Fan H, Li S. Ginsenoside-Rg1 from *Panax notoginseng* prevents hepatic fibrosis induced by thioacetamide in rats. *Eur J Pharmacol* 2010;634:162–9.
- [65] Wu J, Chuang H, Yang L, Lin W. A standardized aqueous extract of *Anoectochilus formosanus*. Ameliorated thioacetamide induced liver fibrosis in mice: the role of Kupffer cells. *Biosci Biotechnol Biochem* 2010;74:781–7.
- [66] Benedetti A, Ferrali M, Casini AF, Pieri S, Comporti M. Foot-edema induced by carbonyl compounds originating from the peroxidation of liver microsomal lipids. *Biochem Pharmacol* 1980;29:121–4.
- [67] Unnikrishnan MC, Sukumaran K, Kuttan R. Free radical scavenging activity of spices and their active ingredients. *Amala Res Bull* 1991;11:76–83.
- [68] Huang Q, Wu L, Tashiro S, Onodera S, Ikejima T. Elevated levels of DNA repair enzymes and antioxidative enzymes by (1)-catechin in murine microglia cells after oxidative stress. *J Asian Nat Prod Res* 2006;8:61–71.
- [69] Guglielmi F, Luceri C, Giovannelli L, Dolara P, Lodovici M. Effect of 4-coumaric acid and 3,4-dihydroxybenzoic acid on oxidative DNA damage in rat colonic mucosa. *Br J Nutr* 2003;89:581–7.

این مقاله، از سری مقالات ترجمه شده رایگان سایت ترجمه فا میباشد که با فرمت PDF در اختیار شما عزیزان قرار گرفته است. در صورت تمایل میتوانید با کلیک بر روی دکمه های زیر از سایر مقالات نیز استفاده نمایید:

لیست مقالات ترجمه شده ✓

لیست مقالات ترجمه شده رایگان ✓

لیست جدیدترین مقالات انگلیسی ISI ✓

سایت ترجمه فا ؛ مرجع جدیدترین مقالات ترجمه شده از نشریات معتبر خارجی